

# Fractional CO<sub>2</sub> laser for vulvovaginal atrophy (VVA) dyspareunia relief in breast cancer survivors

Annalisa Pieralli<sup>1,2</sup> · Maria Grazia Fallani<sup>1</sup> · Angelamaria Becorpi<sup>1</sup> ·  
Claudia Bianchi<sup>1</sup> · Serena Corioni<sup>1</sup> · Manuela Longinotti<sup>1</sup> · Zelinda Tredici<sup>1</sup> ·  
Secondo Guaschino<sup>1</sup>

Received: 22 March 2016 / Accepted: 9 May 2016  
© Springer-Verlag Berlin Heidelberg 2016

## Abstract

**Purpose** The aim of this study was to evaluate the efficacy of fractional CO<sub>2</sub> laser therapy in breast cancer survivors as a therapeutic method for vulvovaginal atrophy (VVA) dyspareunia.

**Methods** 50 patients (mean age 53.3 years) underwent fractional microablative CO<sub>2</sub> laser treatment for dyspareunia in oncological menopause (mean time of menopause 6.6 years). The Gloria Bachmann's Vaginal Health Index (VHI) score was chosen as system to evaluate the presence of VVA and its improvement after the treatment. Intensity of dyspareunia was evaluated using a visual analog scale (VAS).

**Results** Data indicated a significant improvement in VVA dyspareunia ( $p < 1.86e-22$ ) in breast cancer survivors who had undergone 3 sessions of vaginal fractional CO<sub>2</sub> laser treatment. Moreover, VHI scores were significantly higher 30 days post-treatment (T4) ( $p < 0.0001$ ). 76 % of patients were satisfied or very satisfied with the treatment results. The majority (52 %) of patients were satisfied after a long-term follow-up (mean time 11 months). No adverse events due to fractional CO<sub>2</sub> laser treatment occurred.

**Conclusions** The treatment with fractionated CO<sub>2</sub> laser appeared to be a feasible and effective treatment for VVA dyspareunia in breast cancer survivors with contraindications to hormonal treatments.

**Keywords** Vulvovaginal atrophy · Laser · Oncological menopause · Breast cancer survivors

## Introduction

Throughout woman's life cycle, the vaginal epithelium undergoes changes in response to the level of circulating estrogen. After menopause, circulating estrogen levels are dramatically reduced. Numerous cytological transformations follow estrogen reduction, including proliferation of connective tissue, fragmentation of elastin and hyalinization of collagen. These changes may result in granulation, fissures, ecchymosis, telangiectasia and ulcerations, resulting in a condition noted as vulvovaginal atrophy (VVA) [1].

The earliest symptoms of VVA are decreased vaginal lubrication, followed by other vaginal and urinary symptoms that may be exacerbated by superimposed infection, such as burning, itching, bleeding, leucorrhea, dyspareunia and dysuria [2, 3]. These symptoms usually appear 4–5 years after menopause.

This condition affects 20–45 % of women [2, 4] and in contrast to post-menopause vasomotor symptoms it becomes progressive over time and less likely to solve without intervention. Various surveys have shown that VVA symptoms have an adverse emotional and physical impact on female patients and on their partners through unsatisfactory sexual relationship [1].

This aspect is much more threatening for women suffering from premature interruption of ovarian production of estrogens. Examples include cancer treatments, such as surgery, pelvic radiation therapy, chemotherapy or endocrine therapy, that remove ovaries or make them inactive, either temporarily or permanently; use of GnRH agonists to

✉ Annalisa Pieralli  
clabianchi85@gmail.com

<sup>1</sup> Section of Gynecology and Obstetrics, Department of Woman and Child Health, Careggi University Hospital, Largo Brambilla 3, 50144 Florence, Italy

<sup>2</sup> Largo Brambilla 3, 50134 Florence, Italy

manage conditions such as endometriosis and uterine leiomyomas; hypothalamic amenorrhea caused by excessive exercise, disordered eating or postpartum state [3].

Oncological patients can not find relief in hormonal replacement therapy (HRT) which is considered the gold standard treatment for VVA symptoms [5]. A recent report of The North American Menopause Society was inconclusive on the modality of treatment for women affected by premature menopause after breast, ovarian or endometrial cancer, suggesting that for these women the management depends on individual preference or need and it must follow a consultation with oncologist considering the potential risks of hormonal treatment choices [3].

Approximately 50–75 % of breast cancer survivors suffer from one or more VVA symptoms [6].

VVA dyspareunia is an extremely difficult symptom of postmenopausal state and it is common in breast cancer survivors because of low estrogen.

Authors' aim was to assess the efficacy of fractional CO<sub>2</sub> laser therapy in a post-menopausal group of breast cancer survivors as feasible and not contraindicated therapy for VVA dyspareunia as presented in previous literature [6, 7].

## Methods

From June 2013 to June 2015 a prospective descriptive cohort study was conducted at Authors' Centre of Gynecological Laser Surgery and Colposcopy of The University Teaching Hospital of Careggi in Florence. The study protocol was approved by the Hospital Research Review Committee.

*The recruited cohort of population* was constituted by patients with breast cancer, having completed the treatment protocol and final evaluation within the study time.

Patients were enrolled actively by a proposal by their physician aware of single patient's VVA dyspareunia and referred to the centre on a volunteer basis.

At enrollment all patients were asked to have a negative Pap smear not older than a year, were asked to read and subscribe an information white paper illustrating physical principles of the technique, intraoperative and postoperative complications and were informed on the scarcity of literature supporting this procedure [8].

The type of informed consent used was specifically designed for the treatment of menopausal vaginal atrophy with fractional microablative CO<sub>2</sub> laser in agreement with the Helsinki Declaration. The type of informed consent coupled the one previously used by other researching groups [7]. The patients entered the study after the informed consent was obtained.

Enrolled patients accepted to undergo a gynecological visit before the first treatment application and 4 weeks after the last laser application of the treatment protocol. Gynecological inspection included colorimetric pH evaluation [9, 10], speculum insertion to measure vaginal elasticity and colposcopic inspection of the integrity of the epithelium.

Therefore the patients' inclusion criteria in the study group were: oncological menopause (women with current or previous breast cancer), VVA dyspareunia, negative Pap smear.

Exclusion criteria were considered the use of vaginal moisturizing agents and lubricants within 30 days before the inclusion in the study group; the presence of active genital infection during the visit at the enrollment; prolapse stage  $\geq$ II according to pelvic organ prolapse quantification system [11]; previous reconstructive pelvic surgery or topical radiotherapy.

*Treatment protocol* The fractional microablative CO<sub>2</sub> laser (Smart Xide2; V2LR Monnalisa Touch System, DEKA Florence, Italy) was administrated within a protocol providing 3 time points of application at baseline (T1), at 30 days (T2) and at 60 days (T3). The laser energy was set at 30 W power and transmitted through an intravaginal probe with a dwell time of 1000  $\mu$ s, a dot spacing of 1000  $\mu$ m and a smart stack parameter of 1 following a protocol of application suggested by previous Authors [7].

Laser Energy was released by 2 single shots oriented at 45 degrees one from the other so to treat the entire circular vaginal surface covered by the probe which is doted of two opposite focusing points.

All laser application were performed in an outpatient setting, they did not require local anesthesia or not other preparation.

Patients were not prohibited to have sexual activity before or after the treatment sections.

*Data collection and analysis* T1 was the baseline for the collection of the demographic characteristics of patients, verification of inclusion and exclusion criteria and evaluation of VVA presence.

The Gloria Bachmann's Vaginal Health Index (VHI) [12] was chosen by Authors as scoring system to evaluate the presence of VVA and its improvement after the treatment protocol. VHI included five parameters evaluated by colposcopic inspection: elasticity, fluid volume, pH, epithelial integrity and moisture. Each parameter was graded from 1 (worst condition) to 5 (best condition). VVA was defined as a total score at baseline  $<15$  [12]. VHI was repeated 4 weeks after the last laser application (T4) to measure VVA improvement.

Intensity of VVA dyspareunia was evaluated using a visual analog scale (VAS), which is based on a score from

1 to 5, where 1 indicates the absence of symptoms and 5 severe symptoms.

Treatment satisfaction was evaluated at T4 using a 5-point Likert scale (very satisfied, satisfied, uncertain, dissatisfied and very dissatisfied). Treatment was considered satisfactory when patients were very satisfied or satisfied.

Patients were asked to inform physician on intraoperative complications, such as pain at probe insertion, burning, itching, and postoperative ones, such as bleeding, leucorrhea, discomfort.

VHI data reported in the text are expressed as mean with standard deviation of continuous variables and were analyzed by Student's *t* test considering significant a  $p < 0.05$ . VAS data were expressed as median and range of values before and after the treatment and were analyzed by Mood's Median Test to determine whether the median of the two populations were equal or statistically different for a  $p < 0.05$ .

## Results

During the period between June 2013 and June 2015 180 patients voluntarily underwent V2LR treatment for VVA dyspareunia at our Centre.

50 patients affected by breast cancer who had completed the treatment protocol within the study time, with at least 3 months of follow-up, and had never been treated with topic or systemic HRT were eligible to constitute the study group.

Among these, 22 patients (44 %) were assuming adjuvant therapy: 2 (9 %) with Aromatase Inhibitors (AI) and 20 (91 %) with Tamoxifen (TMX). The other 28 patients (56 %) were not assuming any adjuvant therapy.

The mean age of patients was 53.3 years (range 41–66) with a mean time of menopause at the enrollment of 6.6 years (range 1–17). All demographic characteristics of the patients are reported in Table 1.

None of the enrolled patients was missed during the treatment protocol. No patient described intraoperative or postoperative complications with the exception of 12

patients (24 %) who complained for pain at the probe insertion.

VHI was evaluated only for a sample group constituted by the first 36 patients enrolled in the study.

Each sample group member at the enrollment had a VHI score of VVA (<15) with a mean score of  $8.9 \pm 1.7$  st. dev. and enhanced her VHI score at T4 to a mean of  $21.6 \pm 1.6$  st. dev. resulting in a statistically significant recovery ( $p < 0.0001$ ) (Figs. 1, 2). No statistically significant difference ( $p < 0.3$ ) was found in VHI score at T4 between the AI-treated subgroup of patients, the TMX-treated subgroup of patients and the others.

The median of VAS at T1 was 5 (range 1–5) while the median of VAS at T4 resulted 3 (range 1–5). The difference between this two medians of the population who underwent the treatment resulted statistically significant with a  $p < 1.86e-22$  (Fig. 3).

No patient required lubricants or other adjuvant therapies after T4 during sexual activity.

Patient satisfaction with the procedure at T4 was as follows: 18 patients (36 %) were very satisfied, 20 (40 %) were satisfied, 6 (12 %) were uncertain, 6 (12 %) were dissatisfied and 0 were very dissatisfied.

Every patient was called in September 2015 to evaluate long-term treatment effects. The mean time of follow-up was 11 months with a range of 3–25 months. 52 % of patients answered they were very satisfied or satisfied of the treatment results; 26 % were dissatisfied and did not want to repeat the treatment; 22 % were dissatisfied but decided to start a new treatment cycle of laser applications.

## Discussion

Management of VVA dyspareunia in women who have been treated for no hormone-dependent cancers is similar to that for women without a cancer history.

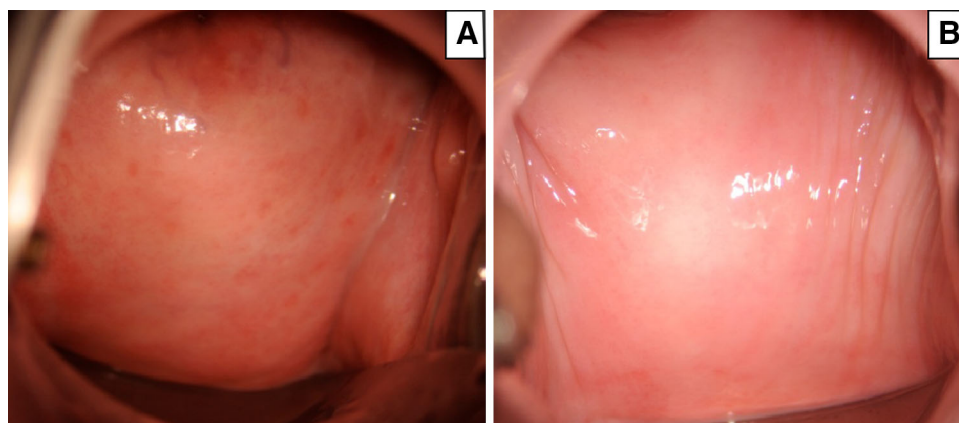
Because the lack of circulating natural estrogens is the primary cause of atrophic vaginitis, hormone replacement therapy is the most logical choice of treatment and has proved to be effective in the restoration of anatomy and the resolution of symptoms. Estrogen replacement restores normal pH levels and thickens and revascularizes the epithelium, increasing the number of superficial cells. Presently, local estrogen therapy, given as estrogen creams, vaginal estradiol tablets and estrogen rings, is the treatment of choice for women with vaginal atrophy who do not have other menopausal symptoms, according to the 2013 NAMS guidelines [3].

For women suffering for hormone-dependent cancers such as breast cancer concerns about adverse effects of exogenous estrogens are described thus, many of these women suffer diminished quality of life as they currently have no safe and effective treatment for their condition.

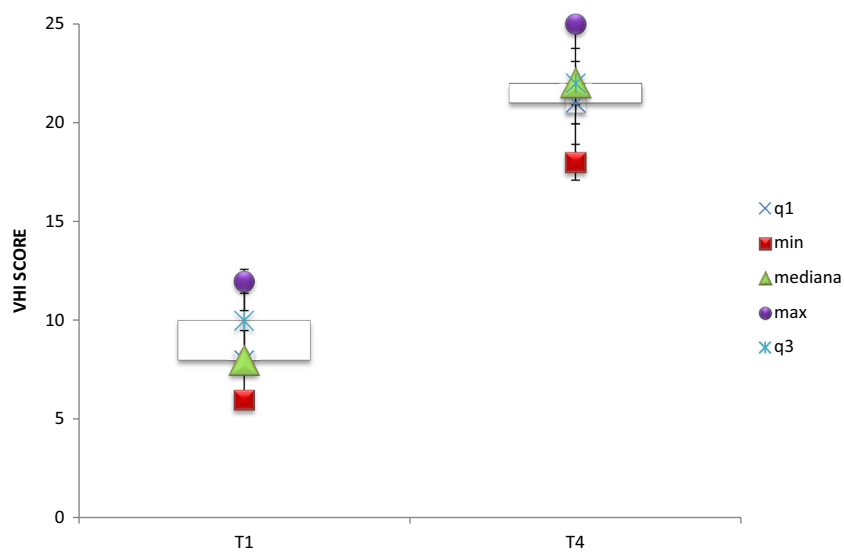
**Table 1** Demographic characteristics of the study population

Age (mean, range)	53.3 (range 41–66)
Time of menopause (mean, range)	6.6 (range 1–17)
Smokers ( <i>n</i> , %)	14 (28 %)
Parity ( <i>n</i> , %)	30 (60 %)
Adjuvant therapy with Tamoxifene ( <i>n</i> , %)	20 (40 %)
Adjuvant therapy with Aromatase Inhibitors ( <i>n</i> , %)	2 (4 %)
No adjuvant therapy ( <i>n</i> , %)	28 (56 %)

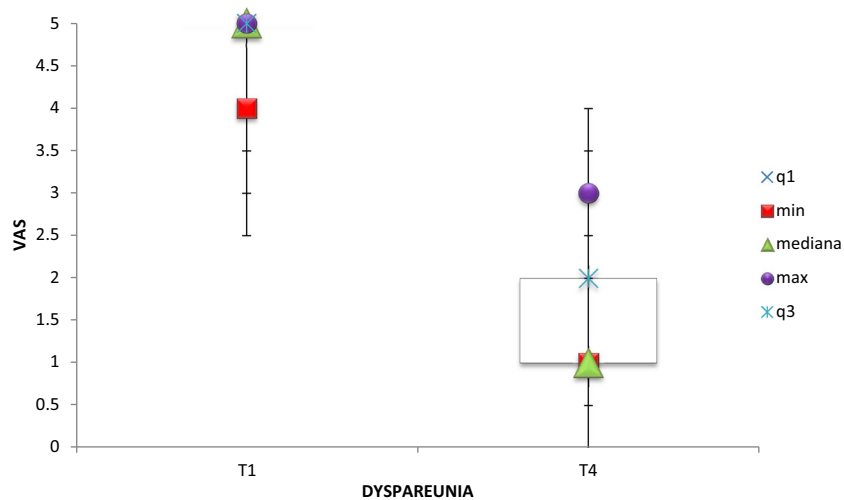
**Fig. 1** Vagina mucosa (a) at enrollment: note petechiae (b) after three applications of fractional CO<sub>2</sub> laser: note the disappearance of petechiae



**Fig. 2** Boxes and whiskers represent the medians, 1st and 3rd quartiles, and minimum and maximum values for VHI score. Statistical analysis was performed using Student's *t* test.  $p < 0.0001$



**Fig. 3** Boxes and whiskers represent the medians, 1st and 3rd quartiles, and minimum and maximum values for VAS dyspareunia score. Statistical analysis was performed using Mood's median test.  $p < 1.86e-22$



Nowadays non-hormonal options are the first line of treatment of VVA dyspareunia in women with breast cancer.

This is the principle reason why there is a clear medical need for an effective “estrogen-free” alternative to treat VVA dyspareunia in this subgroup of postmenopausal women.

VVA dyspareunia is considered by the majority of women as a potentially uncomfortable topic to discuss because of their linkage with sexual health; this is the reason why lubricants and moisturizing agents without pharmacological contents which do not require medical prescription are still the preferred solution [13].

However 40 % of women using lubricants or moisturizing agents as VVA dyspareunia relievers discontinue the treatment because they have concerns about side effects, or find the treatment inconvenient or not having an effect on their symptoms and this behavior often produces a worsening of the VVA dyspareunia [13].

Alternative therapies include selective estrogen receptor modulators (SERMs) and selective tissue estrogenic activity regulators (STEARs).

The most advanced SERM product candidate is ospemifene that acts as an estrogen agonist in the vagina and appears to have no clinically significant estrogenic effect on the endometrium or breast [14, 15]. However the safety of ospemifene has not been demonstrated in women with a prior history or an increased risk of breast cancer.

In this scenario Authors' results show that a physical treatment as the fractional microablative CO<sub>2</sub> laser is safe and produces recovery of VVA dyspareunia.

The induced VVA dyspareunia recovery is statistically significant and independent from the adjuvant use of lubricant agents, qualifying the fractional microablative CO<sub>2</sub> laser as not-chronic method of VVA dyspareunia treatment. Our results agree with other studies present in literature.

In 2011, Gaspar et al. first showed resulting positive changes in biopsy specimens which were treated with fractional microablative CO<sub>2</sub> laser in combination with platelet-rich plasma [16].

Subsequently Zerbinati et al. microscopic and ultra-structural modifications of vaginal mucosa after fractional CO<sub>2</sub> laser treatment. They demonstrated the stimulation of collagen synthesis, the increase of acidic mucopolysaccharides in the ground matrix and the increase of glycogen content in the epithelial cells in the vaginal specimens of patients who underwent fractional CO<sub>2</sub> laser treatment. These findings support the effectiveness of this treatment for the restoration of vaginal mucosa structure and related trophism [17].

In 2014, Salvatore et al. demonstrated for the first time that a treatment with microablative CO<sub>2</sub> laser induced a significant improvement of VVA symptoms. The results of this study showed that laser treatment was feasible, safe, easy to perform and significantly improved both symptoms of VVA and score of vaginal health at 12-week follow-up in women dissatisfied with previous local estrogen therapies [7].

In 2015, Salvatore et al. proved that fractional CO<sub>2</sub> laser treatment is associated with a significant improvement of

sexual function and satisfaction with sexual life in postmenopausal women with VVA symptoms [18].

Latest study of Perino et al. confirmed that fractional CO<sub>2</sub> laser could be a safe, feasible and effective option for the treatment of VVA symptoms without adverse events during the study period [6].

The data from our study indicate a significant improvement in VVA dyspareunia and VHI score in breast cancer survivors who underwent a treatment cycle of three laser applications. In the present study, VHI and thus the improvement of the epithelium trophism achieved by the microablative laser treatment were evaluated for the initial 36 patients enrolled, only up to the statistical significance achievement. This Authors' decision was principally due to the request of a complex colposcopic evaluation that VHI requires and that is perceived as painful by the majority of patients, mostly at T1. Authors decided to avoid vaginal biopsies for the same reason and took for granted proofs the results of Zerbinati et al. [17] on the laser-tissue-interaction.

The majority of women (76 %) declared that they were satisfied or very satisfied with the procedure with an improvement in sexual function and quality of life at T4.

Our results suggest that fractional CO<sub>2</sub> laser treatment may be a viable option in women with severe contraindications to hormonal therapy, such as breast cancer survivors, for whom laser treatment may be utilized as "non-hormonal therapy". Moreover we confirmed that the treatment with fractional CO<sub>2</sub> laser of postmenopausal VVA dyspareunia is feasible, safe and effective without adjuvant agents such as non-hormonal vaginal moisturizers and lubricants.

Although the presents results are of uttermost interest, Authors know data are still biased by the small sample size of the studied group. In contrast to previous studies, the absence of a control group of patients is due to the lack of a gold standard therapy for VVA dyspareunia in breast cancer survivors such as traditional local estrogen therapy as estrogen pessaries or SERMs.

At our knowledge, this is the first study evaluating the feasibility and effectiveness of fractional CO<sub>2</sub> laser treatment in breast cancer survivors and it could guide further research in populations of women with contraindications to hormonal therapies. Moreover, differently from the other studies, a long-term follow-up (mean time 11 months) was included in the study.

Authors would like to underline how this protocol of treatment offered the possibility to discuss with women about the importance of proactive behaviors for preserving sexual function in postmenopausal women. Women were taught on how regular sexual activity helps to maintain vaginal health and increases the likelihood that sexual activity will remain comfortable in the future.

In conclusion, our results showed that treatment with fractional microablative CO<sub>2</sub> laser is safe, well-tolerated and effective in breast cancer survivors with VVA dyspareunia and improves the quality of life in majority of patients.

**Acknowledgments** We thank DEKA M.E.L.A. S.r.l. for technical support.

#### Compliance with ethical standards

**Conflict of interest** The authors declare that they have no conflict of interest.

**Ethical approval** All procedures performed in studies involving human participants were in accordance with the ethical standards of the institutional and/or national research committee and with the 1964 Helsinki declaration and its later amendments or comparable ethical standards.

**Informed consent** Informed consent was obtained from all individual participants included in the study.

#### References

- Nappi RE, Palacios S (2014) Impact of vulvovaginal atrophy on sexual health and quality of life at postmenopause. *Climacteric* 17:3–9
- Santoro N, Komi J (2009) Prevalence and impact of vaginal symptoms among postmenopausal women. *J Sex Med* 6:2133–2142
- The North American Menopause Society. Management of symptomatic vulvovaginal atrophy (2013) 2013 position statement of The North American Menopause Society. *Menopause* 20:888–902
- Lindau ST, Schumm LP, Laumann EO, Levinson W, O’Muircheartaigh CA, Waite LJ (2007) A study of sexuality and health among older adults in the United States. *N Engl J Med* 357:762–774
- Sturdee DW, Panay N (2010) International Menopause Society Writing Group. Recommendations for the management of postmenopausal vaginal atrophy. *Climacteric* 13:509–522
- Perino A, Calligaro A, Forlani F, Tiberio C, Cucinella G, Svelato A, Saitta S, Calagna G (2015) Vulvo-vaginal atrophy: a new treatment modality using thermo-ablative fractional CO<sub>2</sub> laser. *Maturitas* 80:296–301
- Salvatore S, Nappi RE, Zerbinati N, Calligaro A, Ferrero S, Origoni M, Candiani M, Leone Roberti Maggiore U (2014) A 12-week treatment with fractional CO<sub>2</sub> laser for vulvovaginal atrophy: a pilot study. *Climacteric* 17:363–369
- Committee on Gynecologic Practice, American College of Obstetricians and Gynecologists. ACOG Committee Opinion No. 378 (2007) Vaginal “rejuvenation” and cosmetic vaginal procedures. *Obstet Gynecol* 110:737–738
- Panda S, Das A, Singh AS, Pala S (2014) Vaginal pH: a marker for menopause. *J Midlife Health* 5:34–37
- Moradan S, Ghorbani R, Nasiri Z (2010) Can vaginal pH predict menopause? *Saudi Med J* 31:253–256
- Persu C, Chapple CR, Cauni V, Gutue S, Geavlete P (2011) Pelvic organ prolapse quantification system (POP-Q)—a new era in pelvic prolapsed staging. *J Med Life* 75–81
- Bachmann GA, Noveck M, Kelly SL (1992) Long-term non-hormonal treatment of vaginal dryness. *Clin Pract Sex* 8:3–8
- Wysocki S, Kingsberg S, Krychman M (2014) Management of vaginal atrophy: implications from the Revive survey. *Clin Med Insights Reprod Health* 8:23–30
- Constantine G, Graham S, Koltun WD, Kingsberg SA (2014) Assessment of ospemifene or lubricants on clinical signs of VVA. *J Sex Med* 11:1033–1041
- Portman D, Palacios S, Nappi RE, Mueck AO (2014) Ospemifene, a non-oestrogen selective oestrogen receptor modulator for the treatment of vaginal dryness associated with postmenopausal vulvar and vaginal atrophy: a randomised, placebo-controlled, phase III trial. *Maturitas* 78:91–98
- Gaspar A, Addamo G, Brandi H (2011) Vaginal fractional CO<sub>2</sub> laser: a minimally invasive option for vaginal rejuvenation. *Am J Cosm Surg* 28:156–162
- Zerbinati N, Serati M, Origoni M, Candiani M, Iannitti T, Salvatore S, Marotta F, Calligaro A (2015) Microscopic and ultra-structural modifications of postmenopausal atrophic vaginal mucosa after fractional carbon dioxide laser treatment. *Lasers Med Sci* 30:429–436
- Salvatore S, Nappi RE, Parma M, Chionna R, Lagona F, Zerbinati N, Ferrero S, Origoni M, Candiani M, Leone Roberti Maggiore U (2015) Sexual function after fractional microablative CO<sub>2</sub> laser in women with vulvovaginal atrophy. *Climacteric* 18:219–225