

An assessment of the safety and efficacy of a fractional CO₂ laser system for the treatment of vulvovaginal atrophy

Eric R. Sokol, MD,¹ and Mickey M. Karram, MD²

Abstract

Objectives: The aim of the study was to assess the safety and efficacy of a novel fractional CO₂ laser for the treatment of genitourinary syndrome of menopause (GSM).

Methods: Women presenting with GSM and meeting study criteria were enrolled. Examinations at baseline and follow-up (3 mo after final treatment) evaluated dilator tolerance and vaginal pH. Visual analog scales were used to assess pain, vaginal burning, vaginal itching, vaginal dryness, dyspareunia, and dysuria; Vaginal Health Index scores were completed before each treatment and at follow-up; Female Sexual Function Index and Short Form 12 questionnaires were also completed. Participant satisfaction was measured on a 5-point Likert scale (1 = very dissatisfied, 5 = very satisfied). Women received three laser treatments, 6 weeks apart.

Results: Thirty women participated (mean age 58.6 ± 8.8 y). None withdrew or were discontinued due to an adverse event; three were lost to follow-up. Average improvement in visual analog scale scoring was 1.7 ± 3.2 for pain, 1.4 ± 2.9 for burning, 1.4 ± 1.9 for itching, 6.1 ± 2.7 for dryness, 5.1 ± 3.0 for dyspareunia, and 1.0 ± 2.4 for dysuria; improvement in average Vaginal Health Index and Female Sexual Function Index scores were statistically significant ($P < 0.001$). Twenty-five of 30 participants (83%) showed increase in comfortable dilator size at 3-month follow up. Before the second and third treatments, 86.6% (26 of 30) of women reported they were better or much better than at the previous treatment; 26 of 27 women (96%) were reportedly satisfied or extremely satisfied at follow-up.

Conclusions: In this sample, the data suggest that the fractional CO₂ laser is effective and safe for treatment of the symptoms associated with GSM.

Key Words: Dyspareunia – Fractional CO₂ laser – Genitourinary syndrome of menopause – Menopause – Vaginal dryness – Vulvovaginal atrophy.

Genitourinary syndrome of menopause (GSM), also known as vulvovaginal atrophy (VVA), affects quality of life (QoL) and sexual function in as many as 50% of postmenopausal women.¹⁻³ GSM is characterized by atrophy of the mucous membranes and other tissues of the vulva and vagina and occurs as a consequence of reduced circulating estrogen.⁴ Constriction of the introitus and vaginal canal is common and is often associated with reduced sexual activity. Other common manifestations include progressive reduced elasticity of vaginal rugae with thinning of the vaginal lining, reduction of lubrication and symptoms of

itching, burning, dryness, irritation, dysuria, and dyspareunia.⁵ The vagina becomes increasingly prone to trauma and tears, bleeding, and pain as the mucosa thins and becomes more fragile. The prevalence of urogenital infection may also rise as the vaginal secretions became more alkaline, altering the character of vaginal flora.⁶

Many current first-line therapies provide benefit in the treatment of GSM. Vaginal moisturization via topical lubricants may alleviate symptoms. Ospemifene is a well-tolerated synthetic selective estrogen-receptor modulator shown to be somewhat effective for VVA in the treatment of moderate-to-severe dyspareunia.⁷⁻⁸ When not contraindicated, local estrogen therapies are effective when alternatives fail, but compliance reportedly ranges between 52% and 74%,⁹ and some women may not be candidates for estrogen therapy or may decline hormone use.

Device-based options for the treatment of VVA have recently been introduced into the market and have garnered a significant amount of interest. Use of laser for the treatment of VVA was described by Salvatore et al,¹⁰ who recently showed that a fractional CO₂ laser can produce a remodeling of vaginal connective tissue without causing damage to surrounding tissue in an ex vivo study. The fractional CO₂ laser treatment also improved the VVA symptoms of vaginal

Received December 2, 2015; revised and accepted April 19, 2016.

From the ¹Division of Urogynecology and Pelvic Reconstructive Surgery, Stanford University, Stanford, CA; and ²Advanced Urogynecology and Pelvic Surgery, The Christ Hospital, Cincinnati, OH.

Funding/support: This trial was supported by Deka Medical Electronics Laser Associated Società a Responsabilità Limitata (DEKA M.E.L.A. Srl) using the investigators' protocol with oversight by the Stanford University IRB as well as The Christ Hospital IRB; participants did not pay for treatment.

Financial disclosure/conflicts of interest: M.M.K. is a paid consultant of Cynosure, Inc.

Address correspondence to: Eric R. Sokol, MD, Stanford University School of Medicine, 300 Pasteur Drive, Room G332, Stanford, CA 94305. E-mail: esokol@stanford.edu

dryness, vaginal burning, vaginal itching, dyspareunia, and dysuria at 12-week follow-up in a clinical pilot study.¹¹ Other trials have suggested that the laser is feasible, safe, and effective for the treatment of VVA symptoms, and that sexual health and QoL are improved.¹²⁻¹³

This is the first US study of the use of the fractional CO₂ laser for the treatment of symptoms of VVA. The purpose of this study is to evaluate the safety and efficacy of a fractional CO₂ laser for the treatment of GSM.

METHODS

This study was performed at two US centers. The research was conducted according to Good Practice Guidelines and was IRB approved. Informed consent was obtained from all participants. Consecutive women who presented with complaints of GSM were approached for the study and invited to participate if they were healthy, nonsmoking postmenopausal women with an absence of menstruation for at least 12 months. Participants had to exhibit bothersome symptoms of VVA, have less than stage 2 prolapse according to the pelvic organ prolapse quantification system and could not have had any procedures in the anatomical area for the previous 6 months. The use of vaginal creams, moisturizers, lubricants, or homeopathic preparations was not permitted for at least 3 months before study commencement and throughout the entire study period. Thirty women were enrolled (15 at each site).

Exclusion criteria included acute or recurrent urinary tract infection or genital infection; history of thrombophlebitis, acute infections, keloid formation or heart failure; use or anticipated use of antiplatelet treatments, anticoagulants, thrombolytics, vitamin E, or anti-inflammatory within 2 weeks before the treatment phase of the study; concurrent use of medications that increase photosensitivity; presence of pelvic organ prolapse greater than stage II by the pelvic organ prolapse quantification system; previous reconstructive pelvic surgery; and the presence of any disease or chronic condition that could interfere with study compliance.

The primary outcome measure was Visual Analog Scale (VAS) change in six categories of symptoms commonly associated with VVA: vaginal pain, burning, itching, dryness, dyspareunia, and dysuria. VAS was scored on an 11-point scale for each symptom (vaginal pain, burning, itching, dryness, dyspareunia, and dysuria) with 0 being the lowest level (none) and 10 being the highest (extreme). Secondary outcome included (1) assessing the effect of treatment on female urogenital health, using the Gloria Bachmann Vaginal Health

Index (VHI)¹⁴ score (as shown in Table 1); (2) assessing the effect of treatment on vaginal wall elasticity by tracking the maximal tolerable dilator size; (3) assess the effect of treatment on female sexual function using the Female Sexual Function Index (FSFI) questionnaire; (3) assessing the effect of treatment on general QoL using the Short Form 12 (SF-12)-specific questionnaire; (4) assessing the degree of difficulty encountered by the investigators in performing treatment by means of a 5-point Likert scale; (5) and assessing the rate of participant satisfaction with treatment using the Patient Global Impression of Improvement (PGI) via a 5-point Likert scale.

Baseline screening included measurement of vaginal pH and a gynecological examination to assess the condition of the vaginal wall tissue, including a vaginal calibration to determine the maximal dilator each participant could comfortably tolerate; four sizes—extra small (XS), small (S), medium (M), and large (L)—were available. VVA symptoms were assessed using the VAS and baseline VHI scores were also obtained. Participants completed baseline FSFI, SF-12, and general health questionnaires as well.

Each woman received three laser treatments with a fractional CO₂ laser system (SmartXide², MonaLisa Touch, DEKA M.E.L.A. Srl, Florence, Italy) at an interval of 6 weeks (+/-1 wk) between sessions. The procedure was performed in an outpatient setting without any specific preparation such as analgesia or anesthesia required. During treatment, laser energy was transmitted through a tube-shaped vaginal probe with energy deflected at 90° in four directions (the 12, 3, 6, and 9 clock positions) on the vaginal wall tissue. The probe was inserted into the vaginal canal, with two pulses fired; the first at the “noon” position and second at 45° clockwise rotation or “1:30” position, then slowly withdrawn 4 mm (as determined by dedicated markings on the probe) to perform the next treatment similarly until the entire vaginal wall tissue had been treated (Fig. 1). Treatments were performed at 30 W, 1,000 milliseconds dwell time, 1,000 μm spacing, normal scan mode. The Smartstack setting, which controls the number of laser pulses fired at each site, ranged from 1 to 3. Treatment parameters were modulated downward to participant tolerance, if required.

After each session, the participants were evaluated for treatment-related complications and side effects (none, mild, moderate, severe). Participants also assessed their level of discomfort during the treatment using the VAS. Women who were sexually active were instructed to avoid sexual intercourse for 3 days after each treatment, but were otherwise not

TABLE 1. Vaginal Health Index

Score	Overall elasticity	Fluid secretion characteristics	Vaginal pH range	Epithelial mucosa	Moisture
1	None	None	≥6.1	Petechiae noted before contact	None, mucosa inflamed
2	Poor	Scant thin yellow	5.6-6.0	Bleeds with light contact	None, mucosa not inflamed
3	Fair	Superficial, thin white	5.1-5.5	Bleeds with scraping	Minimal
4	Good	Moderate, thin white	4.7-5.0	Not friable, thin mucosa	Moderate
5	Excellent	Normal (white flocculent)	≤4.6	Not friable, normal mucosa	Normal

TABLE 2. Assessment of change in symptoms of VVA^a

Symptom	Baseline to Tx1		Baseline to Tx2		Baseline to Tx3	
	Improvement	<i>P</i>	Improvement	<i>P</i>	Improvement	<i>P</i>
Pain	1.1 ± 2.9	0.051	1.6 ± 3.4	0.025	1.7 ± 3.2	0.009
Burning	1.3 ± 2.5	0.015	1.7 ± 2.4	0.001	1.4 ± 2.9	0.018
Itching	1.1 ± 2.0	0.006	1.6 ± 1.9	<0.001	1.3 ± 1.9	0.001
Dryness	4.8 ± 2.9	<0.001	5.1 ± 2.9	<0.001	6.1 ± 2.7	<0.001
Dyspareunia	4.3 ± 2.8	<0.001	5.3 ± 2.8	<0.001	5.4 ± 2.9	<0.001
Dysuria	0.6 ± 2.1	0.154	0.9 ± 2.2	0.049	1.0 ± 2.4	0.035

VVA, vulvovaginal atrophy.

^aImprovement measured on a Visual Analog Scale (0 to 10, where 0 = none and 10 = extreme), listed as mean ± SD. Cutoff for statistical significance was *P* > 0.05.

given specific activity restrictions. After each treatment, investigators evaluated ease of treatment on a 5-point Likert scale (1 = very difficult, 5 = very easy) and participant satisfaction was evaluated on a similar 5-point Likert scale (1 = very dissatisfied, 5 = very satisfied).

Adverse events were assessed at all visits. At the second and third treatment, participants rated global improvement by completing the PGI on a 5-point scale (1 = much worse, 5 = much better); scores of 4 or 5 indicated perceived improvement.

Participants were required to return for follow-up 3 months after the final treatment. All assessments that were performed pretreatment (vaginal examination, vaginal pH, maximal dilator size, VHI, VAS, PGI, treatment-related discomfort/pain using 5-point Likert Scale, FSFI, and SF-12) were also performed at the follow-up. In addition, women were asked to complete a satisfaction survey regarding the results of the laser treatment using a 5-point Likert scale (1 = very dissatisfied, 5 = very satisfied).

Statistical analysis included appropriate measures for statistical significance (Student’s paired two-sample *t* test) using the standard cutoff for significance of *P* < 0.05 via Microsoft Excel.

RESULTS

For the 30 participants, mean age was 58.6 ± 8.8 years, average onset of menopause was 48.9 ± 7.6 years, and the average age of onset of vulvar and vaginal atrophy symptoms was 51.2 ± 8.3 years. Twenty-seven of the 30 women completed the study and three were lost to follow-up; one failed to

appear after multiple rescheduling of appointments, one had car trouble and missed follow-up, and one left the state and was unavailable for final follow-up. Two women reported mild-to-moderate pain lasting 2 to 3 days and two reported minor bleeding lasting less than 1 day, but none were discontinued due to the occurrence of adverse events.

The primary outcome measure was VAS change in six categories of symptoms commonly associated with VVA: vaginal pain, burning, itching, dryness, dyspareunia, and dysuria. For all six symptom categories, improvement from baseline to the final (third) treatment was statistically significant. Treatment for dryness and dyspareunia showed the most profound improvement; results for dysuria were more modest but still statistically significant. Table 2 displays the VAS results for VVA in the 27 women who presented for 3-month follow-up. The majority of symptom improvement was noted after the first treatment, though participants continued to experience incremental improvement in their VVA symptoms after the second and third treatments.

For secondary outcome measures, VHI scores for the 27 women completing the evaluation at follow-up ranged from 8 to 20 at baseline (mean 14.4 ± 2.9) and from 16 to 25 (21.4 ± 2.9) after three sessions with an overall mean improvement of 7.0 ± 3.1, which was statistically significant (*P* < 0.001).

Vaginal elasticity was evaluated via dilator insertion. Of the 30 enrolled participants, 24 (80%) could comfortably accept an XS or S dilator at the baseline visit, whereas 23 of 24 women (96%) undergoing dilator testing at follow-up could comfortably accept an M or L dilator. Overall, an

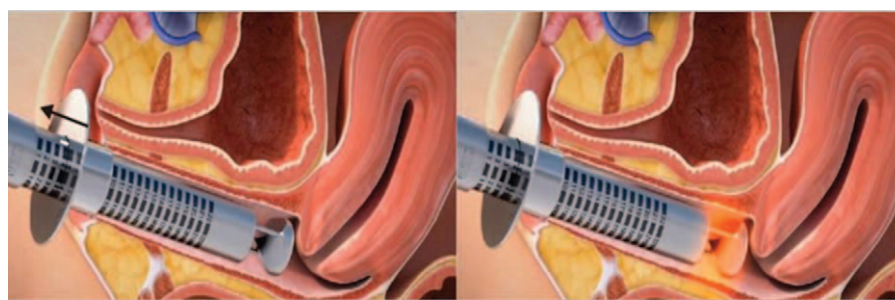


FIG. 1. Diagram of the vaginal probe shown inserted into the vagina (left) with pulse firing (right), deflected in four directions (the 12, 3, 6, and 9 clock positions). Graphics courtesy of DEKA M.E.L.A. Srl, Calenzano, Italy.

increase in dilator size was seen in 25 women (83%) from baseline to follow-up; 5 of 29 (17%) had no change (two women were able to comfortably fit an S-size dilator at all visits, two were able to comfortably fit an M-size dilator at all visits, and one participant was able to comfortably fit an L dilator at all visits). Figure 2 shows dilator size distribution at all visits.

Although part of the overall VHI evaluations, vaginal pH data itself were analyzed separately, and are further detailed in Table 3. Changes were noted but were not statistically significant over the course of the study.

FSFI questionnaires were given at baseline and final follow-up. Of 27 participants undergoing follow-up, 26 completed the FSFI. Scores at baseline ranged from 2 to 25 (mean 11.3 ± 7.3). At follow-up, improvement ranged from -3.7 to 27.2 (mean 8.8 ± 7.3), which was statistically significant ($P < 0.001$).

Of women undergoing 3-month follow-up, 23 completed their second (final) SF-12 questionnaire assessing perceived health. Scores for physical health at baseline averaged 37.2 ± 6.2 with average improvement of 1.6 ± 8.1 (statistically insignificant). Scores for mental health at baseline averaged 43.3 ± 11.9 with average change of -2.6 ± 1.6 (statistically insignificant). Physician investigators rated ease of treatment on a 5-point Likert scale (1 = very difficult, 5 = very easy); scores ranged between 4 and 5 in all cases for all treatments and were virtually unchanged throughout.

Upon study completion, participants were asked to rate satisfaction with treatment on a 5-point Likert scale (1 = very dissatisfied, 5 = very satisfied). Of 27 women at follow-up, 16 were reportedly very satisfied and 10 were reportedly satisfied, with 1 reporting satisfaction as slight, for an overall satisfaction level of 100%. Assessment of global improvement (PGI) on a 5-point Likert scale (1 = much worse, 5 = much better) yielded similar results with approximately 73% of women reporting "much better" ($n = 8$) or "better" ($n = 14$); seven reported "same" and one reported as "worse."

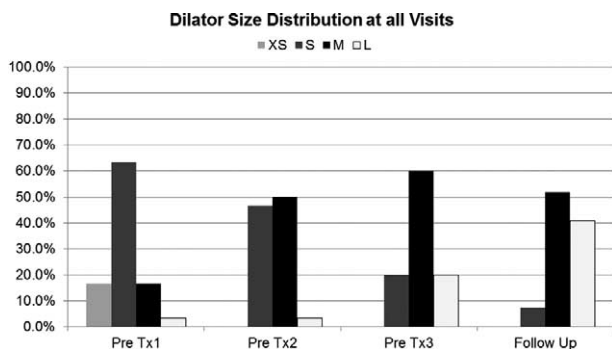


FIG. 2. Distribution of dilator size data for participant population ($n = 30$), shown as percentages of women able to comfortably accept an XS, S, M, or L vaginal dilator at each of four time points (before treatments 1, 2, and 3 as well as final follow up). Three participants were lost to follow-up. L, large; M, medium; S, small; XS, extra small.

TABLE 3. Average vaginal pH at baseline and all study visits^a

	Baseline	Post 1 Tx	Post 2 Tx	Post 3 Tx
Minimum	4.63	4.03	4.03	3.8
Maximum	7.33	7.57	8.03	7.84
Average	5.519	5.620	5.690	5.655
SD	0.705	1.075	1.188	1.381
<i>P</i> value compared with baseline ^b		0.482	0.340	0.517

^aThree participants were lost to follow-up; analyzed data include the subset not lost to follow-up ($n = 27$).

^bpH changes overall were not statistically significant.

DISCUSSION

This pilot study, which is the first US trial of the fractional CO₂ laser system for the treatment of GSM, suggests that fractional CO₂ laser treatment of the vagina is well tolerated by women and leads to significant improvement in the symptoms of GSM. Limitations of this study include the relatively small number of participants enrolled, lack of a control arm, and the short follow-up. Given the small sample size and lack of placebo control to account for participant or investigator expectations possibly confounding the results, data should be interpreted with caution; nevertheless, findings of improvement in GSM symptoms were highly significant. The participants will be followed out to 1 year, and those results will be reported in the future. Direct comparison to existing therapies via randomized controlled investigation is currently underway.

The rationale behind the use of a CO₂ laser for VVA stems from the nature of vaginal wall tissue, which shares many characteristics with normal surface skin despite being more heavily innervated and vascular. Fractional laser therapy has been a mainstay of aesthetic medicine in recent years because it can be both safe and effective for tissue remodeling.¹⁵ Devices use scanning software and mechanical processes to lay down patterns of microwounds, leaving most of the surrounding epithelium intact, which minimizes downtime and speeds re-epithelialization and healing, yet still provides therapeutically relevant thermal damage. Depending on wavelength and energy level (measured as Joules per cm², or J/cm²) the character of microwounding can be ablative and coagulative in nature at varying levels of aggressiveness, with the goal of stimulating neocollagenesis (along with other beneficial processes associated with the healing process) and the subsequent emergence of new, healthy, more youthful skin.

Mainly absorbed by water, the 10,600 nm wavelength CO₂ laser used in this trial is used for soft tissue applications and has received Food and Drug Administration clearance for incision, excision, ablation, vaporization, and coagulation of soft tissue in a variety of medical specialties. This fractional CO₂ laser system has a maximal power of 60 W and energy is delivered through an articulated arm with a delivery accessory connected to its distal end. The system is equipped with a HiScan Dot scanning system and a 360° probe that allows energy emission at 360°. The scanner use is indicated for precise layer-by-layer

tissue ablation to avoiding charring and delivers energy in a uniform, accurate, and controllable manner. Laser energy penetrates to a maximum depth of 200 μm .

Research has demonstrated the tissue remodeling properties of fractional CO₂ lasers in aesthetic medical applications for body regions such as the skin of the face, neck, and chest, with the effect of stimulating the production of new collagen and elastin, bolstering the extracellular matrix.¹⁶⁻²⁰ Reports on the use of the fractional Er:YAG laser (similar to a CO₂ laser in its superficial effect) revealed the capability to improve pelvic floor dysfunction (urinary incontinence and vaginal laxity)²¹⁻²²; an ex-vivo study demonstrated connective tissue remodeling in vaginal wall tissue, without collateral tissue damage or side effects, using predetermined parameters.²³ Laser treatment of vaginal wall tissue has been shown to regenerate the connective tissue of vagina lamina propria.²⁴

Despite limitations, the results of this study were encouraging, with notable perception of global improvement in most participants and for all symptom categories (pain, burning, itching, dryness, dyspareunia, and dysuria) improving by an average of approximately 48% after a single treatment session, with continued improvement after the second and third treatments. The improvement most participants reported in their GSM symptoms after even a single laser treatment suggests that for some women, a single laser treatment may be all that is required, though further study using a larger sample size would be needed to test this conjecture.

These findings are similar to those of three different prospective observational studies. In 2014, Salvatore et al¹¹ reported a 12-week evaluation of the use of pulsed CO₂ laser for the treatment of VVA symptoms in 50 postmenopausal women and noted significant improvement compared with baseline in all of the measured symptoms of VVA. The procedure was well tolerated and no complications or side effects were reported.

Similarly, Perino et al¹² treated 48 study participants and noted significant improvement in all VVA symptoms after three sessions of vaginal fractional CO₂ laser treatment. Overall, 91.7% of women in that trial reported that they were satisfied or very satisfied with the procedure and experienced considerable improvement in QoL. No adverse events due to fractional CO₂ laser treatment were reported.

VVA can negatively impact sexual health and sexual intimacy. Nappi et al²⁵ showed that 58% of women and 61% of men reduced their sexual activity due to VVA, and 35% of women and 14% of men decided to refrain from sex due to VVA. Pain with sexual intercourse associated with VVA was cited as the reason for abstaining from sexual intercourse in 55% of women and 61% of men. The improved FSFI scores we saw in our trial suggest that sexual health improves after treating VVA symptoms with fractional laser. Of note, the FSFI has been shown to be a valid tool regardless of whether a participant engages in sexual intercourse.²⁶

Salvatore et al¹³ also investigated the effects of the fractional microablative CO₂ laser on sexual function and overall satisfaction with sexual life in postmenopausal women with

VVA. Seventy-seven postmenopausal women with VVA symptoms were included and treated with three sessions of a fractional microablative CO₂ laser system (SmartXide², MonaLisa Touch, DEKA M.E.L.A. Srl, Florence, Italy) at 30-day intervals. Sexual function and QoL were evaluated with the FSFI and the SF-12 at baseline and at 12-week follow-up. As in our study, a significant improvement in the total FSFI score and in each domain of the FSFI was observed at 12-week follow-up. Seventeen (85%) out of 20 women who were not sexually active because of VVA severity at baseline regained a normal sexual life at the 12-week follow-up.

In this trial, almost all participants were only able to accept an S or XS dilator at baseline, and at follow-up, 83% were able to accept a larger dilator, indicating an improvement in vaginal elasticity. The ability to use a larger dilator suggests that women would be more likely to have successful vaginal intercourse after laser treatment for GSM. Indeed, some of the women in this trial who had not been able to be sexually active for many years due to pain were able to be sexually active after the laser therapy. Although a larger, placebo-controlled study would be needed to confirm this, the procedure was well tolerated by the participants and it was deemed easy to perform by the investigators, so it seems that fractional CO₂ laser therapy could become a popular therapeutic choice for the treatment of GSM in the future if studies continue to suggest good outcomes. Importantly, 96% of the participants were reportedly satisfied or very satisfied with the treatment.

As a safe, well-tolerated therapeutic alternative for GSM, fractional CO₂ laser therapy may provide a number of key advantages to standard treatment. This might be a particularly useful treatment options for those who cannot use hormone therapies, such as those with estrogen-responsive tumors. Some of the participants in this trial were referred from the oncology clinic and were unable to use vaginal estrogens. Also, our outcomes suggest that symptom improvement occurs rapidly and that a single treatment may provide much of the benefit, making further treatment unnecessary in the immediate future. Further treatment is, however, safe and may bolster outcomes for vaginal dryness and dyspareunia. Lastly, this laser therapy is simple and quick to perform (each treatment takes <2 min) and does not require continuous topical application by the participant, which has been shown to lead to poor compliance with topical therapies and vaginal estrogens.³

An important factor to consider is out of pocket costs because this novel therapy is not currently covered by insurance. It is impossible to perceive how this treatment would be accepted in the context of the relatively elastic modern era of healthcare in the United States. Currently, the costs vary greatly per region from \$1,800 to \$3,000 for three treatments. Future investigations should include comparing the associated cost with the continuous use of vaginal estrogen therapy and the costs associated with fractional CO₂ laser therapy over the same time period.

This is a pilot study and should be interpreted as such; although dilator size data is not easily dismissible given the

objective nature of the measurement, caution should still be exercised due to the obvious limitations including a relatively small sample size and potential for placebo effect. Further study of larger, more racially diverse populations may yield additional information. A control arm, possibly rigged with a sham treatment, may be advantageous in future studies. Additional investigation of fractional CO₂ laser therapy versus alternative therapeutic options such as estrogen therapy or lubricant alone may yield useful information.

CONCLUSIONS

The fractional CO₂ laser used in this study seems to be a safe and effective treatment for GSM, also known as VVA. Tolerability and high satisfaction suggest this modality is a viable and promising alternative to existing therapies for GSM, although further investigations will be needed to confirm these results.

REFERENCES

- Pastore LM, Carter RA, Hulka BS, Wells E. Self-reported urogenital symptoms in postmenopausal women: women's health initiative. *Maturitas* 2004;49:292-303.
- Santoro N, Komi J. Prevalence and impact of vaginal symptoms among postmenopausal women. *J Sex Med* 2009;6:2133-2142.
- Kingberg SA, Wysocki S, Magnus L, Krychman ML. Vulvar and vaginal atrophy in postmenopausal women: findings from the REVIVE (Real Women's Views of Treatment Options for Menopausal Vaginal Changes) survey. *J Sex Med* 2013;10:1790-1799.
- Calleja-Agius J, Brincat MP. Urogenital atrophy. *Climacteric* 2009;12:279-285.
- Mehta A, Bachmann G. Vulvovaginal complaints. *Clin Obstet Gynecol* 2008;51:549-555.
- Portman DJ, Gass MLS. Genitourinary syndrome of menopause: new terminology for vulvovaginal atrophy from the international society for the Study of Women's Sexual Health and the North American Menopause Society. *Menopause* 2014;21:1-6.
- Bachmann GA, Komi JO; Ospemifene Study Group. Ospemifene effectively treats vulvovaginal atrophy in postmenopausal women: results from a pivotal phase 3 study. *Menopause* 2010;17:480-486.
- Wurz GT, Kao CT, Degregorio MW. Safety & efficacy of ospemifene for the treatment of dyspareunia associated with vulvar and vaginal atrophy due to menopause. *Clin Interv Aging* 2014;9:1939-1950.
- Shulman LP, Portman DJ, Lee WC, et al. A retrospective managed care claims data analysis of medication adherence to vaginal estrogen therapy: implications or clinical practice. *J Women's Health (Larchmt)* 2008;17:569-578.
- Salvatore S, Leone Roberti Maggiore U, Athanasiou S, et al. Histological study on the effects of microablative fractional CO₂ laser on atrophic vaginal tissue: an ex vivo study. *Menopause* 2015;22:845-849.
- Salvatore S, Nappi RE, Zerbinati N, et al. A 12-week treatment with fractional CO₂ laser for vulvovaginal atrophy: a pilot study. *Climacteric* 2014;17:363-369.
- Perino A, Calligaro A, Forlani F, et al. Vulvo-vaginal atrophy: a new treatment modality using thermo-ablative fractional CO₂ laser. *Maturitas* 2015;80:296-301.
- Salvatore S, Nappi RE, Parma M, et al. Sexual function after fractional microablative CO₂ laser in women with vulvovaginal atrophy. *Climacteric* 2015;18:219-225.
- Bachmann GA, Notelovitz M, Kelly SJ, et al. Long-term nonhormonal treatment of vaginal dryness. *Clin Pract Sex* 1992;8:12-17.
- Hsiao F, Bock G, Eisen D. Recent advances in fractional laser resurfacing: new paradigm in optimal parameters and post-treatment wound care. *Adv Wound Care (New Rochelle)* 2012;1:207-212.
- Ong MW, Bashir SJ. Fractional laser resurfacing for acne scars: a review. *Br J Dermatol* 2012;166:1160-1169.
- Tierney EP, Hanke CW. Fractionated carbon dioxide laser treatment of photoaging: prospective study in 45 patients and review of the literature. *Dermatol Surg* 2011;37:1279-1290.
- Tierney EP, Hanke CW. Ablative fractionated CO₂ laser resurfacing for the neck: prospective study and review of the literature. *J Drugs Dermatol* 2009;8:723-731.
- Peterson JD, Goldman MP. Rejuvenation of the aging chest: a review and our experience. *Dermatol Surg* 2011;37:555-571.
- Orringer JS, Rittié L, Baker D, Voorhees JJ, Fisher G. Molecular mechanisms of nonablative fractionated laser resurfacing. *Br J Dermatol* 2010;163:757-768.
- Vizintin Z, Rivera M, Fistončić I, et al. Novel minimally invasive VSP Er:YAG laser treatments in gynecology. *J Laser Health Acad* 2012;1:46-58.
- Bump RC, Mattiasson A, Bo K, et al. The standardization of terminology of female pelvic organ prolapse and pelvic floor dysfunction. *Am J Obstet Gynecol* 1996;175:10-17.
- Bachmann G. Urogenital ageing: an old problem newly recognized. *Maturitas* 1995;22(suppl):S1-S5.
- Zerbinati N, Serati M, Origoni M, et al. Microscopic and ultrastructural modifications of postmenopausal atrophic vaginal mucosa after fractional carbon dioxide laser treatment. *Lasers Med Sci* 2015;30:429-436.
- Nappi RE, Kingsberg S, Maamari R, Simon J. The CLOSER (Clarifying Vaginal Atrophy's Impact on Sex and Relationships) survey: implications of vaginal discomfort in postmenopausal women and in male partners. *J Sex Med* 2013;10:2232-2241.
- Wiegel M, Meston C, Rosen R. The Female Sexual Function Index (FSFI): cross-validation and development of clinical cutoff scores. *J Sex Marital Ther* 2005;31:1-20.